

# Utility of endoscopic biopsies in the diagnosis of gastric carcinoma

Trupti P Shetty, Prema Saldanha, Pusalatha Pai

Department of Pathology, Yenepoya Medical College, Mangalore, Karnataka

## Abstract

**Background:** Gastric carcinoma is a common cancer remaining an important public health burden worldwide, especially in developing countries. In India it has been showing a significant rising trend. Endoscopy is widely regarded as the most useful diagnostic test for gastric cancer.

**Objective:** The present study was done to assess the role of endoscopic biopsies in the diagnosis of gastric carcinoma.

**Material and Method:** The biopsies received during a period of 2 years (June 2010-May 2012) were studied following routine processing and using the H and E stain.

**Results:** The present study was done on 56 cases of gastric endoscopic biopsies. Gastric carcinoma occurred in the age range of 42-80 years, peak age of occurrence being the 6th decade of life, with a male to female ratio of 3.4:1. Antrum pyloric region was the most common site, and 49% of the carcinomas were macroscopically ulcers. Adenocarcinoma was the most common histological type found.

**Conclusion:** Gastric carcinoma patients present in advanced stages with an overall poor survival. Incidence and prognosis can be improved by reduction of risk factors and early detection. Endoscopy with biopsy is a useful technique for the diagnosis of gastric carcinoma prior to surgery and the material obtained is sufficient to aid in the classification of the tumours as well as in the grading.

## Introduction

Gastric carcinoma (GC) is the second leading cause of cancer-related deaths<sup>[1]</sup>. It is a common cancer in India with a high incidence in Mizoram<sup>[2,3]</sup> and South India<sup>[4]</sup>.

Adenocarcinomas comprise 95% of all the gastric malignancies. These can be divided into two clinicopathologic categories namely, early gastric cancers which are superficially invasive cancers limited to the mucosa/submucosa, regardless of nodal status, and advanced cancers extending to or beyond the muscularis propria<sup>[1]</sup>. Early gastric cancer causes no symptoms, or nonspecific complaints like dyspepsia. The lack of symptoms often delays the diagnosis of cancer. Consequently 80-90% of the patients present with advanced tumour having poor rates of curability<sup>[1]</sup>. Hence the search continues for novel diagnostic methods that may enable the

early diagnosis of carcinoma. Endoscopy with tissue biopsy is the procedure of choice. Endoscopy is a simple and well tolerated procedure. The direct visualisation of the lesion increases the accuracy of the biopsy site. Endoscopic findings in combination with biopsy plays an important role in the early diagnosis of cancer<sup>[5,6]</sup>. As gastric carcinoma is an important cause of mortality and morbidity, this study was done to evaluate the role of endoscopic biopsies in its preliminary diagnosis.

## Material and Methods

All endoscopic biopsies of clinically suspected cases of gastric carcinoma received from June 2010 to May 2012 (2 years) were included in this study. Clinical details, investigations and endoscopic findings were recorded. The specimens were subjected to histopathological examination following routine paraffin processing and staining with Haematoxylin

## Address for Correspondence

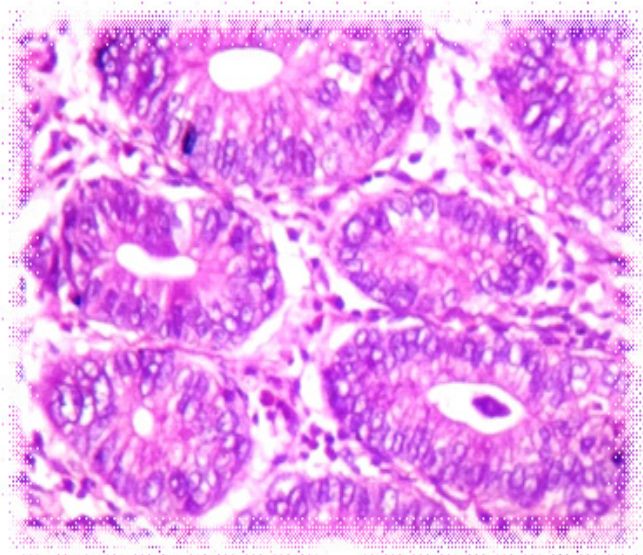
Dr. Prema Saldanha, Professor of Pathology, Yenepoya Medical College, Mangalore -575018, Karnataka, India  
E-mail:-premasaldanha@yahoo.co.in

and Eosin (H and E). The carcinomas were classified and graded according to the WHO classification<sup>[1]</sup>.

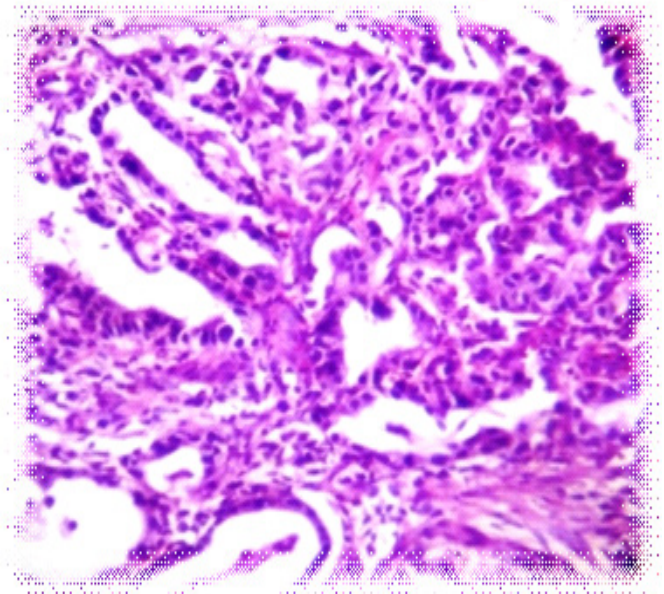
### Results

Of the 166 endoscopic biopsies received during this period, there were 56 cases suspected of gastric carcinoma. Three cases in which material was inadequate due to extensive necrosis were excluded. Out of the 53 cases, 44 cases (83%) were histopathologically diagnosed as carcinoma and 9 cases (17%) were negative. Adenocarcinomas (both intestinal and diffuse types of the Lauren's classification) were the most common with 37 cases (84%) followed by the mucinous type (4 cases), and signet ring cell type (3 cases).

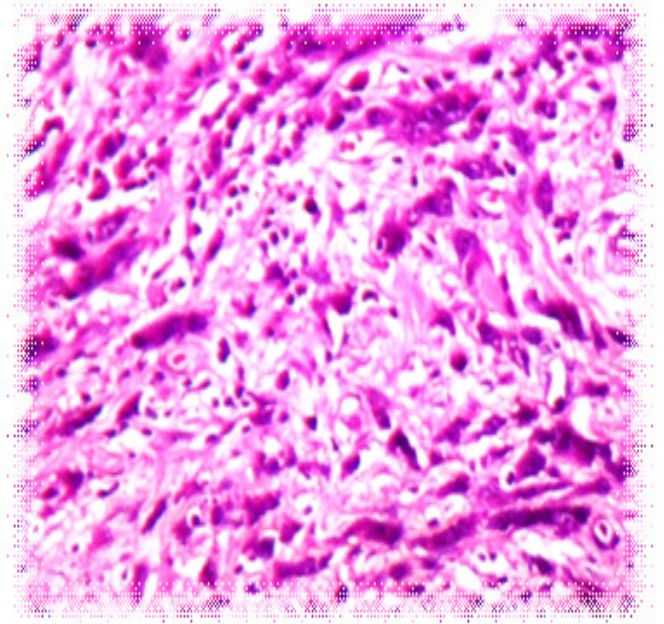
The adenocarcinomas were mostly seen in the 6th decade of life (18 cases) with a male to female ratio of 3.4:1. The cases were more in males in all the age groups, maximum in the age group 60-69 years and in females in the age group 50-59 years. Abdominal pain was seen in 22 cases (50%), followed by dyspepsia (16 cases). Other symptoms included abdominal mass, vomiting, ascites, fever, weight loss and anorexia.



**Figure 1. Well differentiated adenocarcinoma showing glands lined by malignant cells (H&E x40)**



**Figure 2. Moderately differentiated adenocarcinoma showing tumour cells arranged in irregular glands and sheets (H&E x40)**



**Figure 3. Poorly differentiated adenocarcinoma showing tumour cells arranged singly and in small nests without gland formation (H&E x40)**

The tumours were grossly localized in 84% and diffuse in 16% of the cases. The most common site of occurrence of the localized tumours was the antropyloric region forming 64% of the cases followed by body (21%), cardia (10%) and fundus (5%). Macroscopically ulcers were seen in 18(49%)

cases, irregular masses in 15 (40%) cases, polypoid lesions in three (8%) cases, and fungating tumour in one (3%) case. Grading of the adenocarcinomas showed that 16 cases (36.4%) each were well differentiated and poorly differentiated, and 12 cases (27.2%) were moderately differentiated.

There were 4 cases of mucinous carcinoma (with extracellular mucin amounting to more than 50 % of the tumour according to the WHO definition) occurring in the age range of 43-62 years with male predominance (3 cases), two tumours in the antropyloric region, and two, in the body of the stomach.. There were 3 cases of signet ring carcinoma with sheets of signet ring cells in more than 50 % of the tumour according to the WHO definition. The tumours were seen in the pylorus in the age group 50-73 years (two males and one female).

## Discussion

The cause of gastric carcinoma is multifactorial, with both inherited predisposition and environmental influence. They occur in the older age group, the incidence rising progressively with age, with a peak between 50-70 years. Males are affected more than females<sup>[1,7]</sup>. It is extremely rare below the age of 30 years, the median age at diagnosis is 62 years<sup>[1]</sup>. In our study the mean age of occurrence was 60.1 years. The youngest patient was 42 years old. Cancers of the antropyloric region are more common in high-risk regions (Asia, Eastern Europe), whereas tumours of the cardia occur more in low-risk regions (North America, Northern Europe)<sup>[1]</sup>. In this series the antropyloric site was the most common site which is comparable to another study<sup>[1,7]</sup>. The macroscopic types reported vary in different studies<sup>[1,7,8]</sup>. Ulcerated type was the most common type in our study.

Several classification systems have been proposed, of which the WHO and Lauren classification are most commonly used. WHO categorizes the histologic patterns into 5 subtypes: adenocarcinoma (intestinal and diffuse), papillary, tubular, mucinous, and signet-ring cell type<sup>[1]</sup>. The WHO system assigns grades (well, moderately and poorly differentiated) based on the degree of resemblance to metaplastic intestinal tissue. Adenocarcinoma was the most common histological type in our study. Grading of adenocarcinomas is important for

the prognosis and treatment. Majority of the gastric adenocarcinomas are poorly differentiated with an aggressive behaviour<sup>[9]</sup>. In our study both well and poorly differentiated carcinomas occurred with equal frequency.

Histopathological examination using the routine H and E stain is sufficient to make the diagnosis, including typing and grading of the tumours. Occasionally diagnostic problems may arise in cases of diffuse carcinoma which resemble lymphomas, or in cases of signet-ring cell carcinoma in which the cells may have nuclei with a deceptively bland appearance. The presence of cytoplasmic mucus can be confirmed by a mucin stain (Alcian blue-PAS stain). An immunostain for pankeratin (AE1/AE3) or CEA can distinguish muciphages from cancer cells. Overall 95% of tumours are positive for AE1/AE3 and 60-90% are positive for EMA, CK20, CA 19-9, CK 7 and CEA<sup>[10]</sup>.

Endoscopy is widely regarded as an useful procedure to confirm suspected cases of gastric carcinoma. With adequate biopsy material, the diagnostic accuracy of gastric biopsies taken in cases with a suspicion of cancer is 83%<sup>[10]</sup>. Multiple biopsies are useful to avoid false negative diagnoses. Sufficient material is usually obtained to classify and also to grade the tumour. In countries like Japan where gastric cancer is common, this procedure could be useful for mass screening programmes for patients with nonspecific gastrointestinal symptoms. It is also useful to rule out malignancy when endoscopic appearances may be suspicious of cancer<sup>[5,6,11]</sup>.

## References

1. Hamilton SR, Aaltonen LA eds: *World Health Organization Classification of Tumors. Pathology and Genetics of Tumors of the Digestive System*. IARC press: Lyon 2000; 38-6.
2. Phukan KR, Zomawia E, Narain K, Hazarika NC, Mahanta J. *Tobacco Use and Stomach Cancer in Mizoram, India. Cancer Epidemiol Biomarkers Prev* 2005; 14:1892-6.
3. Sharma A, Radhakrishnan V. *Gastric cancer in India. Indian J Med Paediatric Oncol* 2011;32:12-6.
4. Dikshit RP, Mathur G, Shrayu M, Yeole B . *Epidemiological review of gastric cancer in India. Indian J Med Paediatr Oncol* 2011;32:3-11
5. Afzal S, Ahmad M, Mubarik A, Saeed F, Rafi S, Saleem N, et al. *Morphological Spectrum of Gastric Lesions - Endoscopic Biopsy Findings. Pak Armed Forces Medical J* 2006;2:1-6.
6. Gulia SP, Chaudhury M, Noorunnissa N, Balakrishnan CD, Balagurunathan K. *Interpretation of Upper Gastrointestinal Tract Endoscopic Mucosal Biopsies - A Study Conducted in Teaching Hospital in Puducherry, India. Int J Med Health Sci* 2012;1:17-12.
7. Chanda N, Khan AR, Romana M, Lateef S. *Histopathology of Gastric Cancer in Kashmir - A Five Year Retrospective Analysis. J K Science* 2007;9:21-4.

8. *Plummer JM, Gibson TN, McFarlane MEC, Hanchard B, Martin A, McDonald AH . Clinicopathological Profile of Gastric Carcinomas at the University Hospital of the West Indies. West Indian Med J 2005;54:364-8.*
9. *Islam SJM, Ali SM, Ahmed S, Afroz QD, Chowdry R, Hude M. Histopathologic pattern of gastric carcinoma in Bangladesh. JAFMC Bangladesh 2009;5:21-4.*
10. *Owen DA. The stomach. In; Mills SE ed. Sternberg's Diagnostic Surgical Pathology 2010, Lippincott Williams and Wilkins, Philadelphia, 1297-301.*
11. *Khaar HB, Umar M, Khurram M, Khan M, Minhas Z, Goraya F, et al. Endoscopic and Histopathological Evaluation of 306 Dyspeptic Patients. Pak J Gastroenterol 2003;17:4-7.*

Source of Support : **Nil**

Conflict of Interest : **None Declared**