

# Glycogen Storage Disease Type I

Kavitha MM<sup>1</sup>, Kashinakunti Sangappa<sup>2</sup>, Pattar Ramesh<sup>3</sup>,  
Yalameli Bhuvaneshwari<sup>4</sup>, Basavaraj Sajjan<sup>5</sup>, Doble VM<sup>6</sup>

<sup>1</sup>Assistant professor, Department of Biochemistry, <sup>2</sup>Associate professor, Department of Biochemistry,

<sup>3</sup>Assistant professor, Department of Pediatrics, <sup>4</sup>Professor and Head, Department of Pediatrics,

<sup>5</sup>Tutor in the Department of Biochemistry. <sup>6</sup>Professor and Head, department of Pathology  
S. Nijalingappa Medical College Bagalkot-587102, Karnataka. India.

## Abstract

Glycogen storage diseases (GSD) are inherited autosomal recessive disorder. Type-I GSD (Von Gierkes disease) is due to glucose-6-phosphatase defect, which mainly affects liver and is life threatening if not treated. The main features are fasting hypoglycemia, lactic acidosis, hyperuricemia and hyperlipidemia. Here we present a case of six month female baby who presented with fever, abdominal distension and on investigation biochemical parameters were suggestive of type-I GSD.

**Key words:** Glycogen storage disease, Von Gierke's disease

## Introduction

Glycogen storage diseases (GSD) are a group of diseases resulting from a defect in an enzyme required for glycogen synthesis or degradation of glycogen. They result either in the formation of glycogen that has an abnormal structure or in the accumulation of excessive amount of normal glycogen in the specific tissues as a result of impaired degradation[1]. Each type of GSD is because of a specific enzyme deficiency.

GSD-type Ia is due to the deficiency of enzyme Glucose - 6 – Phosphatase, GSD type-Ib is because of endoplasmic reticular glucose – 6-phosphate translocase deficiency, GSD type-Ic is due to defect in microsomal phosphate transport and type-Id is due to defect in microsomal glucose transporter (GLUT-7) (Fig-1)[2]. Glucose -6-phosphatase is the enzyme required for the conversion of glucose – 6 – phosphate to glucose, in the last step of glycogenolysis (breakdown of glycogen). Glucose–6 –phosphatase is present in the hepatic and renal lumen of smooth endoplasmic reticulum (SER). Glucose–6–phosphate translocase present on the smooth endoplasmic reticular membrane of liver, kidney and pancreatic

cells, required for the transport of Glucose –6–Phosphate from the cytosol to the smooth endoplasmic reticular lumen, where Glucose- 6 – Phosphate is converted to glucose by the enzyme Glucose–6–Phosphatase(Figure –II)[2,3].

## Case History

A six month old female child was brought to the pediatric outpatient department, with chief complaints of fever since eight days and abdominal distention. Fever was sudden in onset, progressive in nature. There was no history of chills, rigors, convulsions, cough, cold, vomiting, ear discharge, edema or breathlessness. On examination, baby was afebrile and the weight was 4.25 kg. No pallor, icterus, cyanosis, lymphadenopathy or edema was found. Activity, appearance and reflexes were normal. On per-abdominal examination there was hepatomegaly, other systemic examination was normal. Ultrasonography of the abdomen showed moderate hepatomegaly with diffuse parenchymal disease, no focal lesion, biliary path and portal vein were normal, with mild to moderate ascities. Blood sample was collected for pathological and biochemical analysis. The serum was milky white

---

### Address for correspondence

**Dr Kavitha M M.**

Assistant Professor, Department of Biochemistry, S.Nijalingappa Medical college  
Navanagar, Bagalkot – 587102, Karnataka,India.

Email : mekch@rediffmail.com

(Figure-III). Blood chemistry showed hypoglycemia, hypertriglyceridemia (1070 mg/dL), hypercholesterolemia, hypoproteinemia (3.6 g/dL), hypoalbuminemia (0.7g/dL), reversal of albumin:globulin (A:G) ratio and elevation in Alanine Amino Transferase (ALT) (1868 U/L) and Aspartate Transaminase (AST) (396 U/L). Complete hemogram revealed hemoglobin as 11.4 g/dL, RBC count 4.1 million/mm<sup>3</sup>, WBC count – 18,500/mm<sup>3</sup>, differential leukocyte count was polymorphs – 55%, lymphocytes – 42%, eosinophils-0.3% and platelet count was 3.7 lakh/mm<sup>3</sup>. Peripheral smear showed microcytic hypochromic anemia with neutrophilia. Histopathology revealed enlarged hepatocytes due to accumulation of glycogen.

### Discussion

The present case showed milky white serum, hepatomegaly, episodes of hypoglycemia, hypertriglyceridemia, hypercholesterolemia, hypoalbuminemia, reversal of A:G ratio and elevation of ALT and AST, all the features suggestive of GSD–Ia or Ib.

GSD type Ia and Ib are autosomal recessive, the structural gene for glucose-6-phosphatase is located on chromosome 17q[21], the gene for translocase is on chromosome 11q[23,24]. In GSD Ia and Ib the deficiency of glucose – 6 – phosphate in the liver blocks the final steps of glycogenolysis and gluconeogenic pathways. As expected, these patients are unable to maintain normal blood glucose levels in the fasting state, resulting in episodes of hypoglycemia. Synthesis of ribose can be stimulated by the increased pentose phosphate shunt [2].

Hyperuricemia is caused by both decreased renal clearance and increased production. Lactate competes with uric acid for excretion in the kidney. Accumulation of phosphate esters results in decreased intrahepatic phosphate. This relieves the physiological block on the hepatic AMP – deaminase, thus degradation of adenine nucleotide increases and uric acid is produced.

Hyperlipidemia is a result of both increased synthesis of triglycerides, VLDL, LDL and decreased peripheral lipolysis. The exaggerated

glycolytic pathway produces a generous supply of NADH, NADPH, abundant acetyl CoA and glycerol; thus both substrates and cofactors are available for hepatic triglyceride synthesis. Excess accumulation of glycogen and fat in the liver and kidney leads to decreased functioning of liver and end up in hypoalbuminemia and increased levels of AST and ALT.

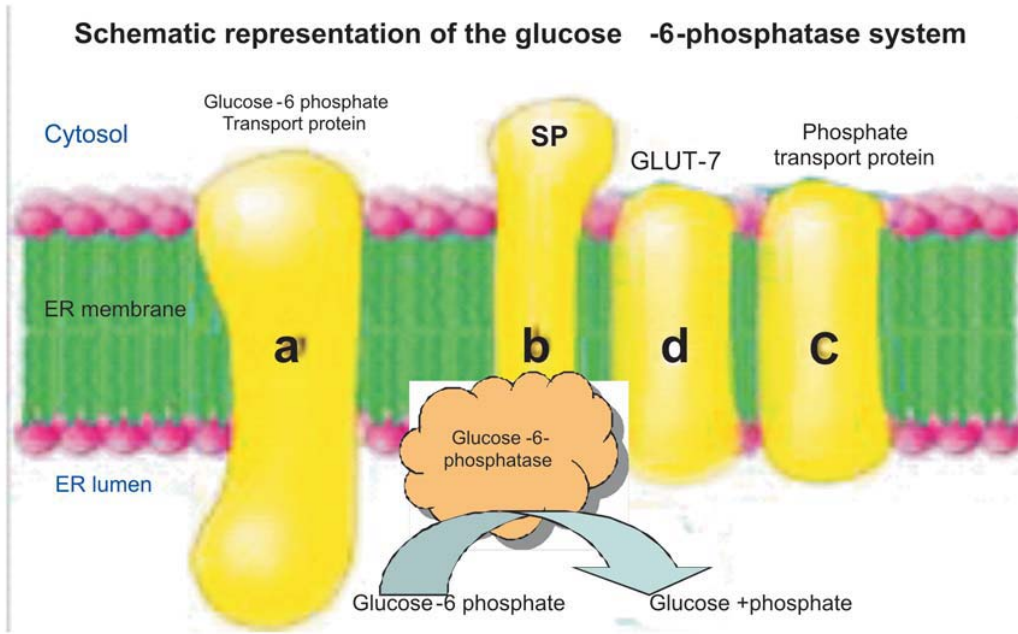
Long term complications in the type I GSD mainly affect liver and other organs. In most of the patients growth is impaired and short stature. There is increased risk of pancreatitis. and hepatic adenomas secondary to the lipid abnormalities. Many have renal stones, nephrocalcinosis, hypertension and altered creatinine clearance. Pulmonary hypertension has been reported, osteoporosis and gout are later complications.

The limitation, while diagnosing the present case was that the patient's parents refused for the estimation of glucose – 6 – phosphatase, glucose – 6 – phosphate translocase and mutation analysis.

Diagnosis can be done by taking liver biopsy, evaluation of enzyme activity and effects of glucagon/epinephrine administration. In our patient liver biopsy revealed enlarged hepatocytes due to accumulation of glycogen and lipids. The patient was treated for respiratory infection with antibiotics and corn starch meal was prescribed to maintain the blood glucose level.

In conclusion, the infant in the present case with hepatosplenomegaly, episodes of hypoglycemia and milky white serum with dyslipidemia, hyperuricemia could be a case of GSD type Ia or type Ib.

Fig-I: Glucose-6-phosphatase model



SP – Stabilising protein  
 ER – Endoplasmic reticulum  
 GLUT-7 – Glucose transporter

Fig-II: Hepatic endoplasmic reticular import, conversion and export of glucose-6-phosphate

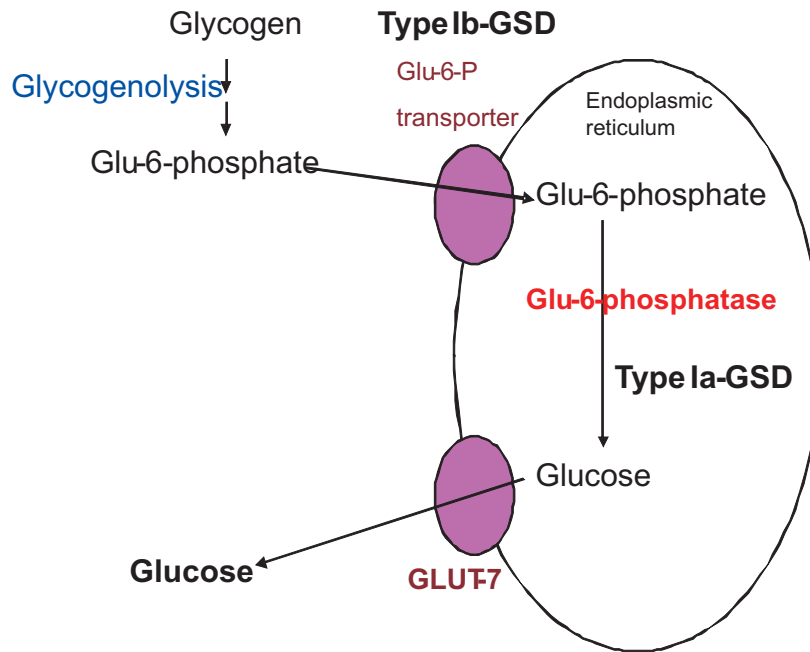


Fig-III: Serum sample of the case and a control


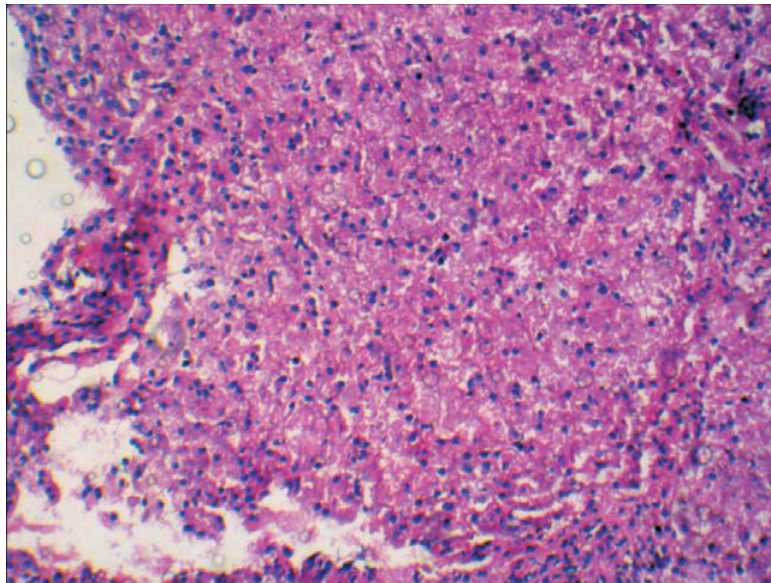


Fig-IV: Histopathology of liver biopsy



Liver biopsy sections from patients with type I glycogen storage disease showing enlarged hepatocytes due to deposition of glycogen

Table I: Biochemical parameters of the case

Sl. No	Investigation	Reported Value
1.	Glucose (RBS)	208.7 mg %
2.	Uric acid	34 mg%
3.	Serum Triglycerides	1070.0 mg %
4.	Serum Total Cholesterol	376.0 mg%
5.	Serum HDL Cholesterol	15.5 mg %
6.	Serum LDL Cholesterol	146.5 mg %
7.	Serum VLDL Cholesterol	214.0 mg %
8.	Total Protein	3.6 g %
9.	Albumin	0.7 g %
10.	Globulin	2.9 g %
11.	S.G.O.T ( AST)	396.0 U/L
12.	S.G.P.T ( ALT)	1868.0 U/L

### References

1. Richard A. Harvey. Glycogen metabolism. In: Lippincott's Illustrated reviews Biochemistry. 5th edition. South Asian edition. 2011: 125-136.
2. Chen YT: Glycogen storage diseases. In: Scriver CR, Beaudet AL, Sly WS, Valle D: The Metabolic and Molecular Basis of Inherited disease, 8th edition, Newyork, McGrew Hill, 2001: 1521-1551.
3. David A, Bender. Metabolism of glycogen. In; Harper,s illustrated Biochemistry. 28th edition. Mc Graw Hill lange publishing division, 2009: 157-164.
4. Priya S, Kishnami and Chen YT: Glycogen storage diseases. In: Nelson text book of paediatrics, 18th edition, South Asia edition, Saunders an imprint of Elsevier, 2008: 601-620.