

A Cadaveric Study of Langer's Muscle and Its Clinical Importance

Maheshwari Myageri¹, Bhavya B.S.², Manisha S. Chougule³

^{1,3}Department of Anatomy, KAHER's JGMM Medical College, Hubballi, Karnataka, India.

²Department of Anatomy, KIMS, Hubballi, Karnataka, India.

Abstract

Background: Langer's muscle is commonly known as axillary arch. It is muscular or musculo-tendinous slip originating from latissimus dorsi muscle and inserts on various anatomical structures in the proximity of axilla. Presence of Langer's muscle can compress neural and vascular structures present in the axilla while being stretched leading to many clinical (complications) conditions and complicate axillary lymph node biopsy or breast reconstruction surgery.

Aims and Objectives: The aim of study is to know prevalence and morphology of Langer's muscle.

Materials and Methods: The study was conducted on 40 embalmed axillae during MBBS undergraduate dissection at department of Anatomy, KIMS Hubli for the period of two years.

Results: The Langer's muscle was present in 2 left axillae out of 40 specimens. In our study, Langer's muscle in both cadavers originated from latissimus dorsi and inserted into coracoid process. In one cadaver Langer's muscle crossed superficial to posterior cord of brachial plexus but deep to other parts of axillary neurovascular structures. And in other cadaver Langer's muscle crossed superficial to axillary nerve and compressing it, but was deep to other axillary neurovascular structures.

Conclusion: The present study is of great importance to know the morphology of Langer's muscle which helps surgeons and oncologists to prevent complications. The Langer's muscle is not uncommon variant and hence should not be ignored.

Key words: Axillary arch, Langer's muscle, Breast reconstruction surgery.

Introduction:

The Langer's muscle is also known as Axillary arch. Many authors have named it by various names such as muscular axillary arch, Langer's axillary arch, axillopectoral muscle, pectorodorsal muscle, arcus axillaris and so on. It was first identified by Alexander Ramsay in 1795, but it was Langer who described it in detail in 1846. Testus named it as "arc axillare de Langer" or Langer's axillary arch^[1,2].

Langer's muscle is a muscular or musculo-tendinous slip originating from the latissimus dorsi muscle and inserts into pectoralis major, pectoralis minor and coracoid process, coracobrachialis or fascia over the biceps brachii^[3,4].

Langer's muscle is not very uncommon variation found in axilla. During physical examination, patient may present with an unknown protrusion in axilla and perplex the surgeons as neoplasm or enlarged local lymph

nodes. The Langer's muscle are found incidentally or sometimes when it is symptomatic. Langer's muscle if present in axilla, when stretched during movement can lead to neurovascular compression, can result in chronic pain, sensation of paraesthesia in upper extremity, thoracic outlet syndrome. Hence presence of Langer's muscle knowledge is very important during differential diagnosis and surgery in axillary region^[1,5]. Therefore the present study was conducted in our department to know the prevalence and morphology of Langer's muscle.

Materials and Methods:

Inclusion criteria-All cadavers available during the period of study.

Exclusion criteria- Cadavers with chest deformity or any surgical scar on chest and axilla were excluded from study.

Address for Correspondence:

Dr. Bhavya B.S.

Department of Anatomy,

KIMS, Hubballi, Karnataka, India.

Email: dr.bhavyabs1984@gmail.com

The study was conducted on twenty embalmed cadavers aged between 60-70 yrs from department of Anatomy, KIMS Hubli during MBBS undergraduate dissection for period of two years. During routine dissection we observed Langer's muscle. Wherever Langer's muscle was found, it was dissected to locate its attachment and measurements were noted. Photograph of the same were taken^[6].

Results: The Langer's muscle was present in two left axillae out of 40 specimens. First specimen showed that Langer's muscle took its origin from the fascia over latissimus dorsi (Figure I) and inserted on coracoid process (Figure. II). Muscle crossed superficial to axillary nerve compressing it and deep to all other axillary neurovascular structures. It was supplied by Thoracodorsal nerve(Figure. III). Langer's muscle was 9.8cm in length and width of 1.5cm.

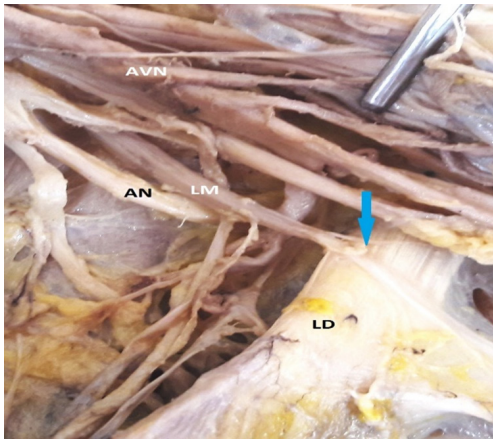


Figure I: Showing origin of Langer's muscle. AN – Axillary Nerve, AVN- Axillary neuro-vascular bundle, LM – Langer's Muscle, LD- Latissimus Dorsi.

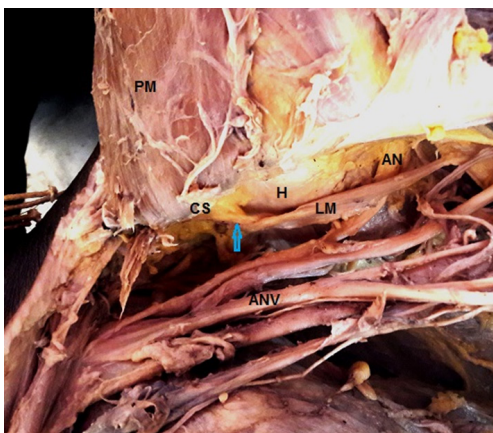


Figure II: Showing insertion of Langer's muscle. AN - Axillary Nerve, ANV- Axillary neuro-vascular bundle, CS- Coracoid Process of Scapula, H- Head of humerus, LM - Langer's Muscle, PM- Pectoralis minor muscle.

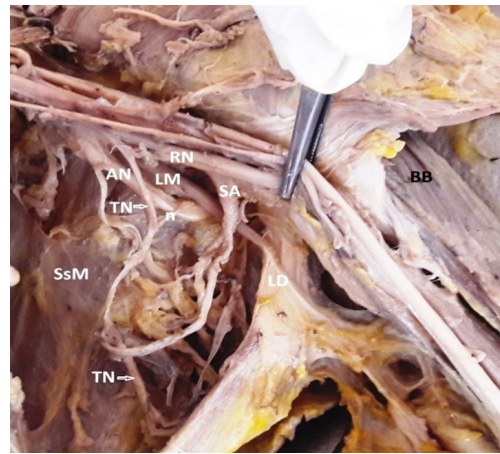


Figure III: Showing nerve supply to Langer's muscle by Thoracodorsal nerve. AN – Axillary Nerve,, LM – Langer's Muscle, LD- Latissimus Dorsi,, n – Nerve supply to LM,RN- Radial nerve,SA- Subscapular Artery,SsM- Subscapular muscle, TN – Thoracodorsal Nerve

Second specimen showed that Langer's muscle took its origin from the fascia over medial aspect of latissimus dorsi. Muscle was inserted on medial border of coracoid process of scapula. Muscle crossed superficial to posterior cord of brachial plexuses but deep to other axillary neurovascular structures. It was supplied by direct branch from posterior cord of brachial plexus. Langer's muscle was 10.8cm in length and width of 1cm (maximum width of muscle belly).

Discussion

Langer's muscle was described with various classification systems by many authors. Testut classified Langer's muscle into complete or incomplete type. The complete type are those which originates from the latissimus dorsi and terminate in the pectoralis major. The incomplete type are those which originate from latissimus dorsi and terminate other than pectoralis major (axillary fascia, corocoid process and so on). Langer's muscle in our study are incomplete type^[1,4].

Jelev et al. proposed another type of classification to classify Langer's muscle into superficial or deep types^[1,2]. Surgical studies may not report complete attachment of Langer's muscle and follow Jelev et.al. classification^[1]. Langer's muscle in our study are superficial type.

The best methods of diagnosing the symptomatic Langer's muscle are MRI and dynamic ultrasonography^[1,7].

In our study 2 left axillae (5%) out of 40 specimens showed presence of Langer's muscle (refer table 1) which was similar to studies done by other authors like Nayak G et.al^[8], Natsis et.al^[9] (4.67%) and Miguel

et.al^[10] (6%). Research studies of maximum number Langer's muscle was recorded by Langer^[11] (25%) where as lowest Langer's muscle was recorded by Turki and Adds (1.07%)^[12]. Comparison of our study with other authors is shown in Table 1^[13].

Table 1: Comparison of our study with other authors^[13].

S. No.	Authors	No of specimens	Langer's muscle	Percentage
1	Langer (1846) ^[11]	4	1	25%
2	Perrin (1871) ^[14]	58	10	17%
3	Miguel. et.al (2001) ^[10]	50	3	6%
4	Turgut. et.al (2005) ^[15]	26	1	3.85%
5	Georgiev. et.al (2007) ^[16]	56	2	3.57%
6	Rizk. et.al (2008) ^[17]	35	3	8.57%
7	Natsis et.al (2010) ^[9]	107	5	4.67%
8	Bharambe VK et.al (2013) ^[4]	30	1	3.33%
9	Turki and Adds (2017) ^[12]	280	3	1.07%
10	Taterra D et.al (2018) ^[1]	1516	15	7%
11	Nayak G et.al (2021) ^[8]	30	2	6.66%
12	Present study (2022)	40	2	5%

Langer's muscle is very important during sentinel lymph node biopsy, lymphadenectomies, mastectomies and breast reconstruction surgeries. The muscle may complicate clinical conditions as lymph nodes hidden behind Langer's muscle might get omitted during surgeries and lead to recurrence of breast cancer and melanoma^[1,18].

Conclusion – The present study is of great value for surgeons and oncologists to know the prevalence and morphology of Langer's muscle to prevent complications. As Langer's muscle is not uncommon variant, hence should not be ignored.

References

- Taterra D, Henry BM, Zarzecki MP et. al. Prevalence and anatomy of the axillary arch and its implications in surgical practice: A meta-analysis. *The surgeon* (2018), <https://doi.org/10.1016/j.surge.2018.04.003>
- Jelev L, Georgiev GP, Surchev L. Axillary arch in human: common morphology and variety. Definition of "clinical" axillary arch and its classification. *Ann Anat* 2007 sep;189(5):473-8.
- Standring S. *Pectoral girdle and Upper limb in Gray's Anatomy*. 40th ed. In: Borley NR, Healy JC, Collins P, Johnson D, Crossman AR, Mahadevan V, Editors. Spain: Churchill Livingstone, Elsevier; 2008. p.777-906.
- Bharambe VK, Arole V. The axillary arch muscle (Langer's muscle): Clinical importance. *Med J DY Patil Univ* 2013;6(3):327-330.
- Clarys JP, Barbaix E, Van Rompaey H, Caboor D, Van Roy P. The muscular arch of the axilla revisited: its possible role in the thoracic outlet and shoulder instability syndromes. *Man Ther* 1996 jun;1(3):133-9.
- Romanes GJ. *Cunningham's manual of practical anatomy*. 15th ed. Vol 1. p.20-34.
- Hong HJ, Choi NJ, Han DH, Ahn MI. Axillary arch: detailed ultrasonographic images with multiplanar CT correlation. *J Med Ultrason* 2015 Jan 14;42(1):121-5.
- Nayak G, Singh G, Pradhan S.A Cadaveric Study of Axillary Arch in Eastern India. *Annals of R.S.C.B*, 2021, ISSN:1583-6258;25(4):1986-1989.
- Natsis K, Vlasis K, Totlis T, et al. Abnormal muscles that may affect axillary lymphadenectomy: surgical anatomy. *Breast Cancer Res Treat* 2010;120(1):77-82.
- Miguel M, Llusa M, Ortiz JC, et al. The axillopectoral muscle (of Langer): report of three cases. *SurgRadiol Anat*. 2001;23(5):341-343.
- Langer K. *Zuranatomie des musculus latissimus dorsi*. *Oester Med Wochenschrift*. 1846;15:16.
- Turki MA, Adds PJ. Langer's axillary arch: a rare variant, and prevalence among Cucasians. *Folia Morphol*. 2017;76(3):536-539.
- Douvetzemis S, Natsis K, Piagkou M, Kostares M, Demesticha T, Troupis T. Accessory muscles of the anterior thoracic wall and axilla. Cadaveric, surgical and radiological incidence and clinical significance during breast and axillary surgery. *Folia Morphol*, 2019;78(3):606-616.
- Perrin JB. Notes on some variations of the pectoralis major, with its associate muscles. *J Anat Physiol*. 1871;5(2):233-244.
- Turgut HB, Peker T, Gulekon N, et al. Axillopectoral muscle (Langer's muscle). *Clin Anat*. 2005; 18(3):220-223.
- Georgiev GP, Jelev L, Surchev L. Axillary arch in Bulgarian population: clinical significance of the arches. *Clin Anat*. 2007;20(3):286-291.
- Rizk E, Harbaugh K. The muscular axillary arch: an anatomic study and clinical considerations. *Neurosurgery*. 2008;63(2):316-319.
- Jeong HS, Jo SW, Lee JH. Variation of the Axillary Arch in Korean Cadaver. *Korean J Phys Anthropol*, 2018;31(4):167-170.

Conflict of interest: Nil

Source of funding: Nil

Date received: Apr 24, 2023

Date accepted: Aug 29, 2023