

# An isolated eyelid Schwannoma- A rare case report

Deeksha Singh, Bhuvan Adhlakha, Shalini Bahadur, Shivani Kalhan

Department of Pathology, Government Institute of Medical Sciences, Greater Noida, Uttar Pradesh, India

## Abstract

**Background:** Schwannoma is benign nerve sheath tumour. These tumours occur anywhere on the but has been rarely reported in the orbital region. The index case patient presented with swelling over left lower eyelid to the ophthalmology OPD. The swelling was slowly progressive, painless, on examination swelling was 1.5 × 1 cm in size, firm to cystic, mobile, and non-tender. A provisional diagnosis of dermoid cyst was made, and the specimen was sent for histopathological examination after excision. Finally, a diagnosis of lateral eyelid schwannoma was made based on microscopic examination and immunohistochemistry.

**Key words:** Benign Neurilemmoma, eyelid tumour, orbit tumour

## Introduction

Schwannoma is an encapsulated benign peripheral nerve sheath tumour, also known as neurilemmoma, composed of proliferation of schwann cells<sup>[1-3]</sup>. These tumors can occur in any nerve in the body<sup>[4]</sup>, although in the ophthalmic region they have been reported in relation to orbit, conjunctiva, sclera and have been rarely reported in eyelid<sup>[5]</sup>. Hereby, we report a rare case of eyelid schwannoma in a 25 year old male.

## Case report

A 25 year male patient presented to the ophthalmology OPD with complaint of swelling over left lower eyelid around outer canthus of eye for one and half year. Swelling was slowly progressive, non mobile and non tender. Patient had no similar swelling on any other part of the body with no history of trauma, previous surgery or any significant family history. On examination swelling was measuring 1.5×1 cm in size, mobile, non-tender, solid to cystic on palpation and no signs of inflammation. Ocular examination revealed no redness, no signs of ptosis, eye discharge, any restricted eye movement and normal visual acuity. A provisional diagnosis thought was Dermoid cyst, excision was planned and tissue was sent for histopathological examination.

We received a grey brown encapsulated soft tissue piece measuring 1.5 × 1 × 1 cm in size. On cut section brownish area identified measuring 1 × 1 cm in size, no cystic area identified.

Microscopic examination shows a tumour comprised of hypercellular (Antoni A) showing palisading

of nucleus with verocay bodies and hypocellular (Antoni B) loose and myxoid areas. No areas of cystic degeneration, atypia, mitotic figure were noted. Histopathological provisional diagnosis thought was a schwannoma, and immunohistochemistry with S100 was performed which came out to be, strong nuclear positive. The final diagnosis of Benign Schwannoma of lateral eyelid was made, the follow up period of the patient was uneventful.

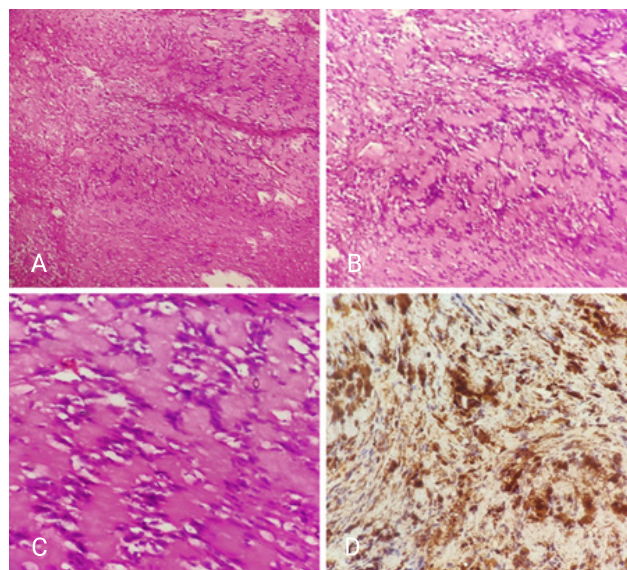


Figure 1

**Figure A, B:** Section shows hypercellular (Antoni A) and hypocellular (Antoni B) areas (40x, 100x H&E).

**Figure C:** Section shows formation of verocay bodies (400x H&E).

## Address for Correspondence:

**Dr. Deeksha Singh**

Senior Resident, Department of Pathology

Government Institute of Medical Sciences, Greater Noida. Uttar Pradesh, India

Email: deekshapatho003@gmail.com

**Figure D:** Section shows positive nuclear stain for S100 (400x H&E).

### Discussion

Schwannoma is the most common peripheral nerve sheath tumour of adult, arising from the schwann cells of peripheral nerve sheath<sup>[4]</sup>. Most of schwannoma are benign in nature but malignant transformation can occur in few cases. It occurs sporadically, only few cases are associated with neurofibromatosis type 2, which may be due to a loss of function mutation in the protein merlin. Isolated schwannoma of eyelid is rare, multiple schwannomas seen in neurofibromatosis<sup>[2]</sup>. In our case patient presented with single isolated swelling, with no family history of neurofibromatosis 1 and 2.

Clinical presentation of schwannoma varies, it may present as lump having pain and numbness or sometimes it may be asymptomatic. It can affect the people of any age (median age 19-63), it rarely occurring in children only 3 cases reported so far in children<sup>[6]</sup>. According to study done by Lopez male to female ratio was 3:2. There is no sex prediction. Most commonly it occurs on extremities, eyelid is very rare location, according to study done by Lopez-Tizon schwannoma represent only 0.1% of eyelid neoplasm. Schwannoma on eyelid can be confused with dermoid cyst, chalazion, sweat gland tumour, sebaceous gland carcinoma and other neurogenic and soft tissue tumour<sup>[1,2]</sup>. Poor prognosis factors seen in cases where cells are fusiform or epithelioid in shape and there is presence of melanin granules<sup>[4]</sup>.

### There are various variants of schwannoma:

1. Ancient schwannoma: hyalinization, nuclear atypia seen but no other features suggestive of malignancy seen.
2. Cellular schwannoma: Only Antoni A areas seen. Verocay body not seen.
3. Epithelioid schwannoma: composed of epithelioid schwann cells with moderate amphophilic cytoplasm and occasional nuclear pseudo inclusions. Stroma is myxoid and hyalinised, with thick blood vessel wall.
4. Microcystic/ Reticular schwannoma: Bland spindle cells in myxoid background, with formation of microcystic structure.
5. Neuroblastoma schwannoma: Rare variant, formation of rosette like structure surrounded by schwann cells.
6. Plexiform schwannoma: Rare variant, associated with Neurofibromatosis 2. Involve multiple nerve fascicles<sup>[2]</sup>.

Grossly it is well circumscribed, encapsulated and microscopically it shows hypercellular Antoni A and hypocellular Antoni B areas along with nuclear palisading (formation of verocay bodies). It shows strong nuclear S100 positivity. In our case patient came with probable diagnosis of dermoid cyst which is based on history and clinical examination and complete excision was done, and tissue had been sent for histopathological examination. So based on gross features, microscopic examination and strong nuclear positivity of S100, a final diagnosis of schwannoma of lateral eyelid was made, which is a rare presentation<sup>[4]</sup>.

### Acknowledgement

Department of pathology, Government Institute of Medical Sciences, Greater Noida

### References

1. Gelincik I. Right upper eyelid schwannoma in a child: A case report. *J Clin Exp Pathol.* 2012;2:116.
2. Poonam P. Giant Schwannoma of upper eye lid in a male child of 13 years—A rare case report. *histopathology.* 2017;201:203.
3. Morsi NH, AlMansouri OS, AlMansour EM. Isolated eyelid Schwannoma: A rare differential diagnosis of lid tumor. *Saudi J Ophthalmol.* 2017 Apr-Jun;31(2):112-114. doi: 10.1016/j.sjopt.2017.02.005. Epub 2017 Feb 28. PMID: 28566981; PMCID: PMC5436379.
4. Patil SB, Kale SM, Jaiswal S, Khare N. Schwannoma of upper eyelid: A rare differential diagnosis of eyelid swellings. *Indian J Plast Surg.* 2010 Jul;43(2):213-5. doi: 10.4103/0970-0358.73456. PMID: 21217985; PMCID: PMC3010787.
5. Ittarat M, Srihachai P, Chansangpetch S. Case report of eyelid schwannoma: A rare presentation in a child. *Am J Ophthalmol Case Rep.* 2018 Dec 5;13:56-58. doi: 10.1016/j.ajoc.2018.12.005. PMID: 30582072; PMCID: PMC6288314.
6. Coutinho MD, Meyer I, Jungmann P, Souza Filho JP. Schwannoma of the left superior eyelid in a 10-year-old child. *Revista Brasileira de Oftalmologia.* 2014 Mar;73:117-9.

Conflict of interest: Nil

Source of funding: Nil

Date received: Aug 22, 2023

Date accepted: Nov 11, 2023