

# To compare Gross & Ferguson and Mitchell-Banks repair techniques in children with congenital inguinal hernia

Nitin Jain<sup>1</sup>, Yogesh Kumar Sarin<sup>2</sup>,

<sup>1</sup>Department of Pediatric Surgery, Maulana Azad Medical College, New Delhi, India

<sup>2</sup>Department of Pediatric Surgery, Lady Hardinge Medical College, New Delhi, India

## Abstract

**Aims:** To compare operating time, early complication(s) and outcome of Gross & Ferguson and Mitchell-Banks repair techniques in children with congenital inguinal hernia.

**Materials and Methods:** A prospective randomized study including boys aged 1-12 years, was conducted over one year. The patients were allocated in two interventional groups based on the repair viz. Gross and Ferguson and Mitchell-Banks group. After hernia repair, the patients were followed up on the day of surgery and at one week for early complications.

**Results:** Fifty patients were enrolled. Mean operating time in Mitchell-Banks technique was significantly more than Gross and Ferguson technique ( $p=0.00012$ ). The incidence of fever in two groups was similar. Scrotal edema was statistically significant in MB group on both Post-Operative Day -1 and 7 ( $p=0.023$  and  $p=0.034$ ). No patient in either group had wound infection or scrotal hematoma on POD-1. One subject (2%) had scrotal hematoma in MB group on POD-7. A total of 12 subjects (24%) had Surgical Site Infection on POD-7. There was statistically higher incidence of SSI on Day-7 in GF group (32%) as compared to MB group (16%) ( $p=0.018$ ).

**Conclusion:** GF technique had lesser operating time, less incidence of scrotal edema and hematoma though higher rate of surgical site infections. In this respect, GF technique can be used as a simple and safe procedure.

**Key words:** Gross and Ferguson technique, Mitchell-Banks technique, Inguinal Hernia, Scrotal edema, Scrotal hematoma, Surgical Site Infection

## Introduction

Inguinal hernia (IH) is a common condition in infancy and childhood with IH repair being the most common pediatric surgical modern procedure<sup>[1]</sup>. The estimated prevalence rate of inguinal hernia is reported to be 1-5% and 9-11%, in full-term and premature neonates respectively<sup>[2,3]</sup>.

Inguinal hernia is repaired via two common techniques namely Gross and Ferguson (GF) and Mitchell-Bank (MB). In GF repair, the fascia of the external oblique muscle and the external ring is incised and high ligation of the sac at inner ring is done. But opening the external oblique muscle could result in some complications such as per-operative nerve and vessel injury, postoperative pain, edema and hematoma<sup>[4,5]</sup>. The MB technique was first described in 1882; in which herniotomy is performed without incision of

external oblique muscle and external ring which results in minimal tissue injury<sup>[6-9]</sup>. There are few retrospective studies, which compare inguinal hernia repair with and without opening external oblique muscle. In spite of the high incidence of inguinal hernia in pediatric population, there is no agreement among pediatric surgeons about the preferred operative procedure. Hence, this study was planned to compare the incidence of early complications between two conventional methods of pediatric inguinal herniotomy.

## Methodology

A prospective randomized study was conducted at the Department of Pediatric Surgery of a tertiary care center in India. All males aged 1-12 years presenting to the outpatient department (OPD) with uncomplicated unilateral inguinal hernia between November 2016

## Address for Correspondence:

**Dr. Yogesh Kumar Sarin**

Department of Pediatric Surgery

Lady Hardinge Medical College New Delhi-110001, India

Email: yksarin@gmail.com

to October 2017 (1 year) were enrolled in the study after taking consent from the parents. Children with any other medical or surgical conditions (congenital or acquired) were excluded from the study. Children were allocated in two interventional groups based on the two types of hernia repair techniques (with and without opening the external oblique muscle fascia) by block randomization and matching with respect to age and side of hernia. To avoid selection bias random blocks were used. In our study blinding was not possible for the operating surgeon. Approval of the Institutional Ethics Committee was taken.

In GF, inguinal herniotomy was performed after opening inguinal canal, hernial sac was then separated from cord structures and ligated [Fig.1]. In MB, inguinal herniotomy was done through the superficial inguinal ring, by dissecting the hernia sac from vas deferens and vessels without opening inguinal canal and then ligating sac at level of pre-peritoneal fat by applying gentle traction on superficial inguinal ring [Fig.2].

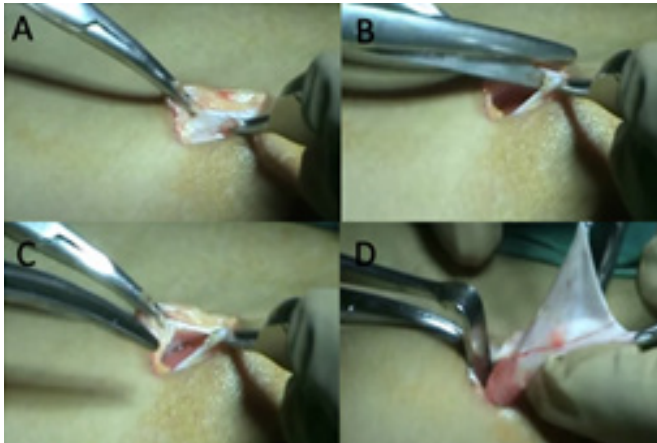

Fig.1 showing steps of GF technique, A. showing external oblique aponeurosis, B & C. external oblique aponeurosis is cut, D. hernial sac identified and separated from cord structures

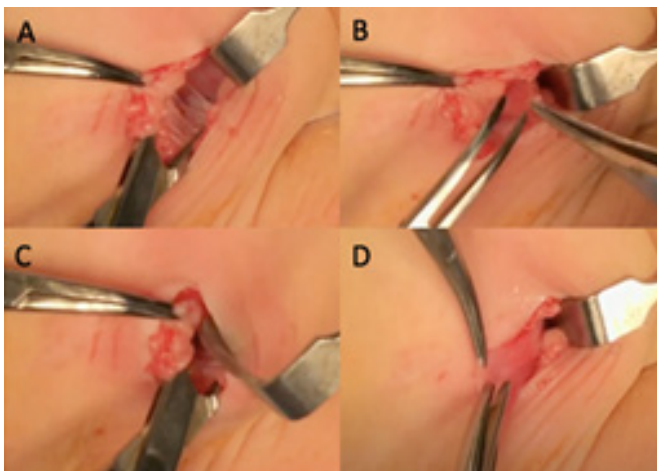


Fig.2 showing steps of MB technique, A. showing superficial inguinal ring, B & C. retracting superficial

inguinal ring, D. hernial sac identified and separated from cord structures

All operations were performed by single pediatric surgeon and a single pre-operative surgical prophylaxis dose of injectable ceftriaxone was given to all patients. The patients were discharged on first post operative day (POD-1) and were followed up in OPD on seventh postoperative day (POD-7). Fever, scrotal edema, scrotal hematoma, and wound infections were classified as short-term complications. Fever was measured with thermometer on POD-1 and POD-7. Patients with persistently increased temperature of  $>100^{\circ}$  F were labelled as having fever.

Scrotal edema was assessed on clinical examination. Scrotal ultrasound was performed only in cases of scrotal swelling with pain, redness and tenderness to document scrotal hematoma.

Wound infection was perceived as superficial or deep. Clinical signs like raised local temperature, redness, pain and tenderness were included in assessment of superficial site infection (SSI), while significant wound gaping and purulent discharge were included in deep wound infection. Though pus culture or wound swab cultures were not sent, whenever SSI was suspected clinically, empirically combination of Amoxicillin, and Clavulanic acid was administered orally for 7 days.

The data was entered into Microsoft excel and analyzed using the SPSS version 17. Descriptive statistics in the form of mean and standard deviations or proportions was used. For quantitative data, the difference between the means of the two groups was compared by t-test. For qualitative data, Chi-Square or Fischer's exact test was used to observe difference between proportions for independent groups. P value of  $<0.05$  was considered statistically significant.

## Results

A total of 50 patients were enrolled and 25 each were allocated to the two interventional groups. Mean age of boys who underwent surgery by GF technique was 6.57 years, while mean age of boys subjected to MB technique was 4.88 years. 38 subjects (76%) had inguinal hernia on the right side, while 12 subjects (24%) had left inguinal hernia (Table I).

**Table I: Observations of the patients enrolled in the study**

OBSERVATIONS	GF TECHNIQUE	MB TECHNIQUE	p- value
Mean age (years)	6.57	4.88	0.232
Side of hernia (left/right) (%)	16/84	32/68	-
Operating time (minutes;%):			
<30 minutes	22 (88%)	6 (24%)	0.00012
30-45 minutes	3 (12%)	14 (56%)	
>45 minutes	0	5 (20%)	
Fever (POD 1) (n)	2 (8%)	6 (24%)	0.247
Scrotal edema (POD 1) (n)	1 (4%)	8 (32%)	0.023
Scrotal edema (POD7) (n)	2 (7%)	8 (32%)	0.034
Scrotal haematoma (POD7) (n)	0 (0)	1 (4%)	0.312
Wound infection (POD7) (n)	8 (32%)	4 (16%)	0.0185

GF - Gross & Ferguson repair technique, MB - Mitchell-Banks repair technique, POD - Post Operative Day

With GP technique, the duration of surgery was less than 30 minutes in 22 subjects (88%), 30-45 minutes in 3 (12%). With MB technique, the duration of surgery was less than 30 minutes in 6 subjects (24%), 30-45 minutes in 14 subjects (56%) and >45 minutes in 5 subjects (20%). Mean operating time was 26.44 minutes and 38.44 minutes in GF technique and MB technique respectively. Duration of surgery was significantly shorter with GF technique than with MB technique ( $P < 0.05$ ).

Overall, fever was present in 8 subjects (2/25 in GF technique and 6/25 in MB technique) on POD-1 while no subject had fever on POD-7. The incidence of fever in two groups (GF vs. MB) was statistically non-significant ( $p=0.247$ ).

Scrotal edema was present in 9 (18%) subjects on POD-1 (1/25 in GF technique and 8/25 in MB technique) and 10 subjects (20%) on POD-7 (2/25 in GF technique and 8/25 in MB technique). It was significantly more in MB group as compared to GF group on both POD-1 and POD-7 ( $p=0.023, 0.034$ ).

Scrotal hematoma was not seen in any patient on POD-1 in either group, while 1 subject (2%) (MB group) had scrotal hematoma on POD-7. The difference was not statistically significant.

Wound infection was not present in any subject on POD-1, while 12 patients (24%) developed wound infection on POD-7. There was statistically higher

incidence of SSI on Day-7 in GF group as compared to MB group ( $p=0.0185$ ).

## Discussion

No significant correlation was seen between age or side of the hernia repair and outcome in our study. The baseline characteristics in our study were found to be statistically similar in two studied groups ( $P > 0.05$ ). So, age and side distribution don't impact upon the outcome with either of the two techniques used. Similar correlation was found in other studies like Nazem et al.<sup>[4]</sup> and Askarpour et al.<sup>[7]</sup>

Duration of surgery was significantly shorter in inguinal hernia repair with GF technique than with MB technique ( $P < 0.05$ ). On the contrary, Nazem et al.<sup>[4]</sup> showed that the GF technique ( $15.15 \pm 0.57$  minutes) took comparatively longer time as compared with MB technique (mean operating time  $13.83 \pm 0.52$  minutes). This difference could be due to familiarity with the GF technique in our institution. Technically also, as the obliquity of inguinal canal gets increased with increasing age, so surgery without incising external oblique muscle becomes more strenuous and require more muscle retraction to ligate the sac at the neck, thus poses more problems.

The incidence of fever in two groups (GF vs. MB) was statistically similar ( $P > 0.05$ ). In study by Nazem et al.<sup>[4]</sup>, incidence of fever was 6.1% (2 patients) in MB technique and 9.1% (3 patients) in GF technique, which was statistically not significant. Although statistically insignificant, but we observed higher incidence of fever in MB technique that could be explained based on longer operating time and consequently higher surgical stress.

Scrotal edema was significantly more in MB group as compared to GF group on both POD-1 and POD-7 and the difference was statistically significant. Higher incidence of scrotal edema in MB group can be explained in post-operative period owing to the fact that there is more muscle stretching, tissue stress and retraction in MB technique. In contrast, Nazem et al.<sup>[4]</sup> and Turk et al.<sup>[6]</sup> found a higher, though not statistically significant, incidence of scrotal edema with GF technique. None of the patient with scrotal edema required aspiration in our study.

No patient had scrotal hematoma on POD-1 in our study and there was no statistically significant difference with regard to the incidence of scrotal hematoma on Day-7 between the two groups. Nazem et al.<sup>[4]</sup> had similarly quoted incidence of scrotal hematoma in MB and GF techniques as 6.1% and 3% respectively; the difference was not statistically significant. However, Askarpour et al.<sup>[7]</sup> found the

incidence of scrotal hematoma reversed- 3.3% with GF technique vs. 1.25% with MB technique; here too the difference was not statistically significant. In our study, the only patient who had scrotal hematoma didn't require any intervention and responded to compressive dressing and antibiotics.

In our study, wound infection was not present in any subject on POD-1 while, 12 subjects (24%) had SSI on POD-7. There was statistically higher incidence of SSI on Day-7 in GF group (n=8, 32%) as compared to MB group (n=4, 16%) (p=0.0185). It seems that we have overestimated the incidence of SSI as we used a subjective criterion of redness of wound as evidence of SSI; ideally, we should have taken wound cultures that may not have been possible as none of the patients had pus discharge from the incision site. None of the patients had any deep surgical site infection.

Nazem et al<sup>[4]</sup> had found that the incidence of wound infection was similar in both technique (~3%), while Turk et al<sup>[6]</sup> found higher incidence of wound infection with the GF technique as compared to the MB technique (0.8% vs.0.5%), though the difference was statistically insignificant. Sarin et al.<sup>[10]</sup> had found the incidence of wound infection was very low (0.3%) in a retrospective study of 1369 patients undergoing hernia repair. Carneiro et al<sup>[11]</sup> did a six-year retrospective review of herniotomies in 380 children (up to the age of 10 years) and found 16 (4.2%) patients having postoperative wound infection. In our study single dose of pre-operative antibiotic was given to all patients, no patient was given antibiotics in post-operative period but whenever SSI was suspected (12 patients), empirically combination of amoxicillin and clavulanic acid was administered orally for 7 days, as other studies by Vaze et al<sup>[12]</sup> & Joda AE<sup>[13]</sup> showed no statistical significant difference in incidence of surgical site infection between those who didn't receive antibiotics and those who got antibiotics in post-operative period.

Limitations of our study include that it was a single center study with small sample size.

### Conclusions:

This study showed that inguinal hernia repair performed with GF technique in children do not lead to an increase in complications as it has less operating time, less incidence of scrotal edema and hematoma but slightly higher incidence of SSI. In this respect, GF technique can be used as a simple and safe procedure. High incidence of SSI in our study suggests the need of more meticulous dissection and strict aseptic measures to be used in future. Bias towards the GF technique could also be because of

more familiarity with this technique at our institution.

### References

1. Glick PL and Boulanger SC. Inguinal hernias and hydroceles. *Pediatric surgery*. 2006;2:1172-92.
2. Grosfeld JL. Current concepts in inguinal hernia in infants and children. *World J Surg*. 1989 Sep-Oct;13(5):506-15. doi: 10.1007/BF01658863. PMID: 2573200.
3. Snyder CL. Inguinal hernias and hydroceles. In *Ashcraft's pediatric surgery 2010 Jan 1* (pp. 669-675). WB Saunders.
4. Nazem M, Dastgerdi MM, Sirousfard M. Outcomes of pediatric inguinal hernia repair with or without opening the external oblique muscle fascia. *J Res Med Sci*. 2015 Dec;20(12):1172-6. doi: 10.4103/1735-1995.172985. PMID: 26958052; PMCID: PMC4766824.
5. Ferguson AH. Oblique Inguinal Hernia.: Typic Operation For Its Radical Cure. *Journal of the American Medical Association*. 1899 Jul 1;33(1):6-14.
6. Türk E, Memetoglu ME, Edirne Y, Karaca F, Saday C, Güven A. Inguinal herniotomy with the Mitchell-Banks' technique is safe in older children. *J Pediatr Surg*. 2014 Jul;49(7):1159-60. doi: 10.1016/j.jpedsurg.2013.09.065. Epub 2013 Oct 23. PMID: 24952808.
7. Askarpour S, Peyvasteh M, Sherafatmand S. Comparison between inguinal herniotomies with and without incising external oblique aponeurosis: a randomized clinical trial. *Arq Bras Cir Dig*. 2017 Jul-Sep;30(3):187-189. doi: 10.1590/0102-6720201700030006. PMID: 29019559; PMCID: PMC5630211.
8. Kurlan MZ, Wels PB, Piedad OH. Inguinal herniorrhaphy by the Mitchell Banks technique. *J Pediatr Surg*. 1972 Aug-Sep;7(4):427-9. doi: 10.1016/0022-3468(72)90015-2. PMID: 5049854.
9. Jabłoński J, Bajon K, Gawrońska R. Long-term effects of operative treatment of inguinal hernias in children comparison of different techniques. *Przegl Pediatr*. 2007;37:44-7.
10. Sarin YK, Wakhlu A, Agarwal LD, Sharma AK. Inguinal herniotomy in children: a decade's experience. *Indian pediatrics*. 1993 Nov 1;30(11):1363-6.
11. Carneiro PM, Rwanyuma L. Occurrence of contralateral inguinal hernia in children following unilateral inguinal herniotomy. *East Afr Med J*. 2004 Nov;81(11):574-6. PMID: 15868966.
12. Vaze D, Samujh R, Narasimha Rao KL. Risk of surgical site infection in paediatric herniotomies without any prophylactic antibiotics: A preliminary experience. *Afr J Paediatr Surg*. 2014 Apr-Jun;11(2):158-61. doi: 10.4103/0189-6725.132816. PMID: 24841018.
13. Joda AE. Are prophylactic antibiotics justified in pediatric patients with inguinal hernia repair?. *Mustansiriya Medical Journal* 2016 Jan 8;15(2):24.

Conflict of interest: Nil

Source of funding: Nil

Date received: Jan 25, 2022

Date accepted: May 16, 2022